

# Clinical outcome after 450 revascularization procedures for moyamoya disease

## Clinical article

**RAPHAEL GUZMAN, M.D.,<sup>1,3</sup> MARCO LEE, M.D., PH.D.,<sup>1,3</sup> ACHAL ACHROL, B.S.,<sup>1,3</sup> TERESA BELL-STEPHENS, R.N.,<sup>1,3</sup> MICHAEL KELLY, M.D.,<sup>1,3</sup> HUY M. DO, M.D.,<sup>1-3</sup> MICHAEL P. MARKS, M.D.,<sup>1-3</sup> AND GARY K. STEINBERG, M.D., PH.D.<sup>1,3</sup>**

*Departments of <sup>1</sup>Neurosurgery and <sup>2</sup>Radiology, and <sup>3</sup>Stanford Stroke Center, Stanford University School of Medicine, Stanford, California*

**Object.** Moyamoya disease (MMD) is a rare cerebrovascular disease mainly described in the Asian literature. To address a lack of data on clinical characteristics and long-term outcomes in the treatment of MMD in North America, the authors analyzed their experience at Stanford University Medical Center. They report on a consecutive series of patients treated for MMD and detail their demographics, clinical characteristics, and long-term surgical outcomes.

**Methods.** Data obtained in consecutive series of 329 patients with MMD treated microsurgically by the senior author (G.K.S.) between 1991 and 2008 were analyzed. Demographic, clinical, and surgical data were prospectively gathered and neurological outcomes assessed in postoperative follow-up using the modified Rankin Scale. Association of demographic, clinical, and surgical data with postoperative outcome was assessed by chi-square, uni- and multivariate logistic regression, and Kaplan-Meier survival analyses.

**Results.** The authors treated a total of 233 adult patients undergoing 389 procedures (mean age 39.5 years) and 96 pediatric patients undergoing 168 procedures (mean age 10.1 years). Direct revascularization technique was used in 95.1% of adults and 76.2% of pediatric patients. In 264 patients undergoing 450 procedures (mean follow-up 4.9 years), the surgical morbidity rate was 3.5% and the mortality rate was 0.7% per treated hemisphere. The cumulative 5-year risk of perioperative or subsequent stroke or death was 5.5%. Of the 171 patients presenting with a transient ischemic attack, 91.8% were free of transient ischemic attacks at 1 year or later. Overall, there was a significant improvement in quality of life in the cohort as measured using the modified Rankin Scale ( $p < 0.0001$ ).

**Conclusions.** Revascularization surgery in patients with MMD carries a low risk, is effective at preventing future ischemic events, and improves quality of life. Patients in whom symptomatic MMD is diagnosed should be offered revascularization surgery. (DOI: 10.3171/2009.4.JNS081649)

**KEY WORDS** • moyamoya disease • moyamoya syndrome • bypass surgery • revascularization • stroke • outcome

**M**OYAMOYA disease is an uncommon cerebrovascular disease characterized by idiopathic stenosis or occlusion of the bilateral terminal internal carotid arteries resulting in the characteristic development of an abnormal vascular network in the areas of the arterial occlusions,<sup>40</sup> first described by Takeuchi and Shimizu<sup>43</sup> in 1957. The etiological course of MMD remains unknown.

*Abbreviations used in this paper:* EEG = electroencephalography; MCA = middle cerebral artery; MELAS = myopathy, encephalopathy, lactic acidosis, and stroke; MMD = moyamoya disease; mRS = modified Rankin Scale; STA = superficial temporal artery; TIA = transient ischemic attack.

Although the recent literature shows a rising number of cases of moyamoya diagnoses in non-Asian populations, the exact incidence has not been determined.<sup>13</sup> A survey in the western US found an annual incidence of 0.086/100,000 persons.<sup>43</sup> The numbers are much lower than those reported for the Asian population, with the newest data in that population reporting an incidence of 0.54/100,000/year and a prevalence of 6/100,000.<sup>28</sup>

Outcomes after surgical treatment of adult and pediatric patients with MMD<sup>11,25,37</sup> and moyamoya syndrome (that is, secondary moyamoya phenomenon associated with a syndrome)<sup>19,37</sup> have been previously reported. However, most large series are found in the Asian literature where direct revascularization techniques are prevalent.

In the Western literature, larger series (those including > 100 cases) have reported mainly on pediatric patients and on patients largely treated with indirect revascularization techniques.<sup>37</sup>

Here we present a consecutive series of 329 patients with MMD undergoing 557 revascularization procedures and detail our analysis of demographics, clinical characteristics, and long-term outcomes after revascularization surgery.

## Methods

### *Patient Population*

All consecutive patients with MMD treated microsurgically by the senior author (G.K.S.) at Stanford University Medical Center were included in the study. The study period was between January 1991 and August 2008. All data were prospectively entered into a database. All patients were diagnosed based on clinical presentation, neuroimaging studies including MR imaging, cerebral perfusion studies including acetazolamide challenge (SPECT and/or Xe CT), and 6-vessel cerebral angiography according to published guidelines.<sup>9</sup> As previously described,<sup>22</sup> patients presenting with unilateral MMD were included in the study. Patients with moyamoya syndrome (that is, secondary moyamoya phenomenon associated with a systemic syndrome [such as Down syndrome or neurofibromatosis with angiographic findings of MMD]) were also included in the study. The angiograms were interpreted by 2 neuroradiologists (M.P.M. and H.M.D.) and the senior author. Only symptomatic patients were selected for surgery. Patients with arterial narrowing caused by atherosclerotic disease undergoing bypass surgery were excluded from the study.

### *Surgical Techniques*

In bilateral MMD, we first revascularize the clinically more symptomatic side (the hemisphere with frequent TIAs). If no lateralizing signs or symptoms are present, we prefer to revascularize the nondominant side first. The main reason for this approach is for the increased incidence of transient neurological episodes after surgery on the dominant hemisphere. The second side is usually revascularized 1 week after the first surgery, as tolerated by the patient. Direct revascularization, consisting of an STA-MCA bypass, is the first choice. The size of the frontal and parietal branch of the STA is determined on angiography of the external carotid artery, and the decision is made whether the frontal or parietal branch is to be used based on artery diameter. In patients in whom either the STA or the MCA is considered too small (< 0.6 mm) or too fragile for a direct bypass, indirect revascularization procedures, such as encephaloduroarteriosynangiosis or encephaloduroomyosynangiosis,<sup>37</sup> are applied. Indirect revascularization techniques such as pedicled omental transposition or free omental transplantation used in the beginning of this series have been abandoned. Techniques for revascularization surgery have been extensively described in the literature.<sup>3,4,10,20,22</sup> All procedures are performed under mild hypothermia with a target core temperature of 33°C. Cooling

is achieved either with surface cooling (a cooling blanket) or by placing an intravenous catheter (InnerCool Therapies) into the inferior vena cava as described previously.<sup>39</sup> Patients undergo intraoperative somatosensory evoked potential and continuous EEG monitoring. If changes in somatosensory evoked potentials or EEG activities occur, anesthetic techniques are adapted, including increasing mean arterial blood pressure. During clamping of the M4 branch the patient is given thiopental to achieve burst suppression of the EEG. After surgery, patients are kept in the intensive care unit overnight with strict blood pressure control, usually a mean arterial blood pressure between 80 and 100 mm Hg in adults and lower in children. Subcutaneous low-molecular weight heparin (in adults) and aspirin (in adults and children) are started the day after surgery. Magnetic resonance imaging studies including diffusion-weighted imaging are performed the day after surgery to exclude the presence of new strokes. Patients are usually discharged from the hospital 3–4 days after surgery.

### *Clinical Follow-Up*

Patients are clinically evaluated 1 week after the second surgery (after the first surgery in patients with unilateral MMD), and thereafter at 6 months, 36 months, and 10 years. Additionally, periodic phone follow-up evaluations are performed in all cases. Patients are studied by MR imaging, cerebral perfusion studies (SPECT and/or Xe CT), and cerebral angiography at 6 months, 36 months, and 10 years. Selective external carotid artery injections are included to evaluate the bypass patency and extent of revascularization.

Surgical morbidity was defined as new neurological deficits lasting 24 hours or longer after revascularization surgery and associated with a new infarct or hemorrhage on MR or CT imaging in the first 30 days after the revascularization procedure.

A minimum of 6 months of follow-up information was obtained for all patients included in the outcomes analysis. The occurrence of stroke, hemorrhage, TIA, and headache was recorded at clinical follow-up. Activities of daily living were quantified using the mRS as described elsewhere.<sup>1</sup> The mRS score was recorded prior to surgery and at the latest clinical follow-up available, with none < 6 months after surgery.

### *Statistical Analysis*

Categorical variables were analyzed using the chi-square test. Univariate and multivariate logistic regression analyses were performed to determine risk factors for postoperative morbidity. Risk of subsequent stroke and death was determined using the Kaplan-Meier method, with comparisons made using the log-rank statistic. Differences were considered statistically significant at  $p < 0.05$ .

## Results

Between January 1991 and August 2008, a total of 329 patients underwent 557 revascularization procedures. In 65 patients the follow-up duration had not yet reached 6 months at the time of this study and the cases were there-

## Outcome after bypass surgery for moyamoya disease

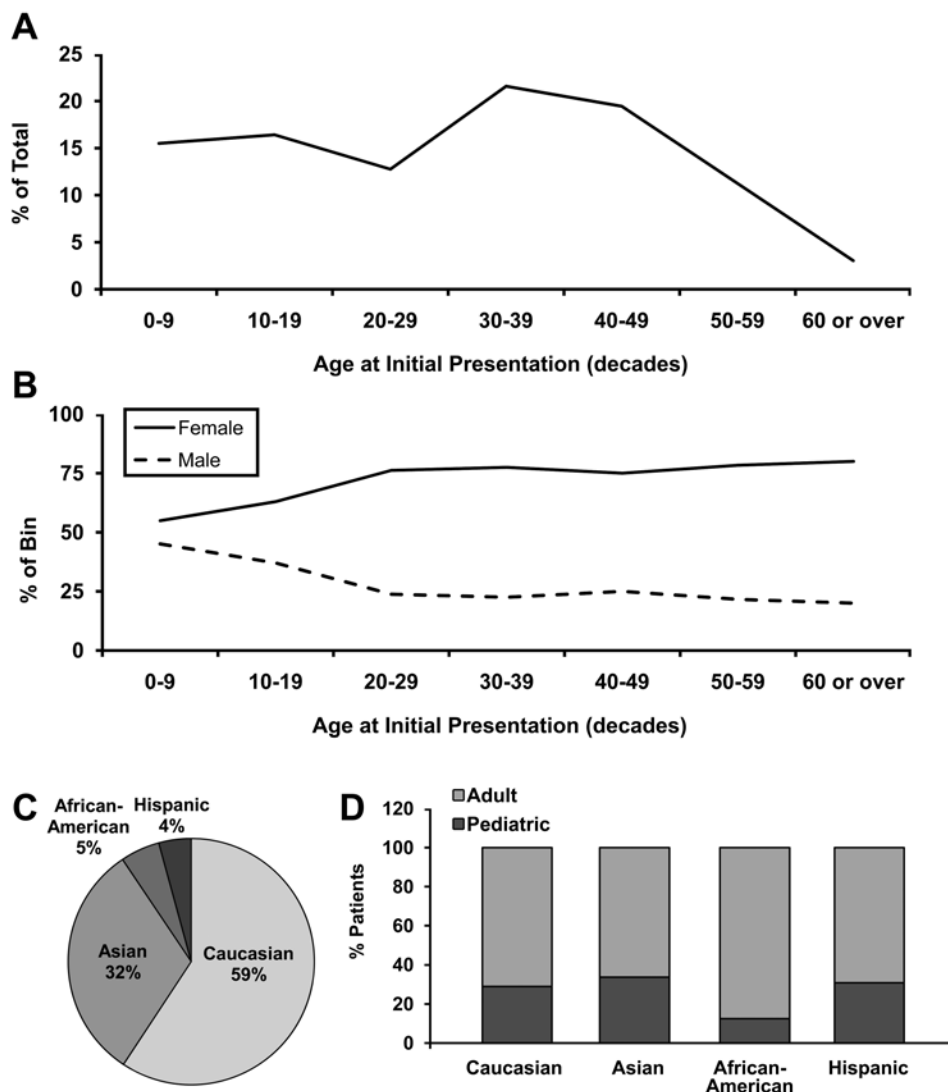


FIG. 1. A: Bimodal distribution of age at initial presentation, with peaks in the 10–19 and 30–39 bins. B: Sex breakdown of each bin: consistently two-thirds female and one-third male in each bin except for the 0–9 bin where the ratio is nearly 1:1. C and D: Ethnic distribution (C) and percentage of adult and pediatric patients at presentation in the ethnic subgroups (D).

fore excluded from the outcomes analysis. A minimum of 6 months of follow-up was obtained in the remaining 264 patients undergoing 450 revascularization procedures with a mean follow-up of 4.9 years (range 0.5–16.8 years, median 3.2 years).

### Demographics and Clinical Presentation

There were 272 adult patients whose mean age was 39.5 years (range 18–69 years) and 96 pediatric patients with a mean age of 10.1 years (range 1–17.9 years). A typical bimodal age distribution was observed (Fig. 1A). There was a 1:1 female/male distribution in the young children, which changed to 3:1 in the second decade of life and thereafter (Fig. 1B). Bilateral disease was present in 73.3% of patients and was independent of ethnicity. Ethnic distribution and age at presentation are shown in Fig. 1C and D. Presenting symptoms are shown in Fig. 2 upper and lower. While 14.6% of adult patients presented with intracerebral hemorrhage, hemorrhage was exceed-

ingly rare as a presenting symptom in the pediatric group with 2.1% ( $p = 0.001$ ). Sixty-one percent of the patients had  $\geq 2$  presenting symptoms.

### Surgical Results

A total of 557 surgeries were performed: 389 in adult and 168 in pediatric patients. A total of 498 surgeries were direct revascularization procedures. In adult and pediatric patients 96.6 and 67.2% of hemispheres, respectively, were treated with direct bypass ( $p < 0.0001$ ). In adults the reason for indirect surgery was an MCA or STA  $< 0.6$  mm in 9 patients and a previous failed indirect encephaloduroarteriosynangiosis surgery that left no STA branch available in 2 patients. In pediatric patients, the STA or  $M_4$  segment size (or fragility) was the determining factor in all cases. The mean age of pediatric patients undergoing indirect surgery was 6.5 years whereas it was 11.2 years in children undergoing direct surgery ( $p < 0.05$ ). The youngest child to receive a direct bypass was 4.3 years of age. At a mean

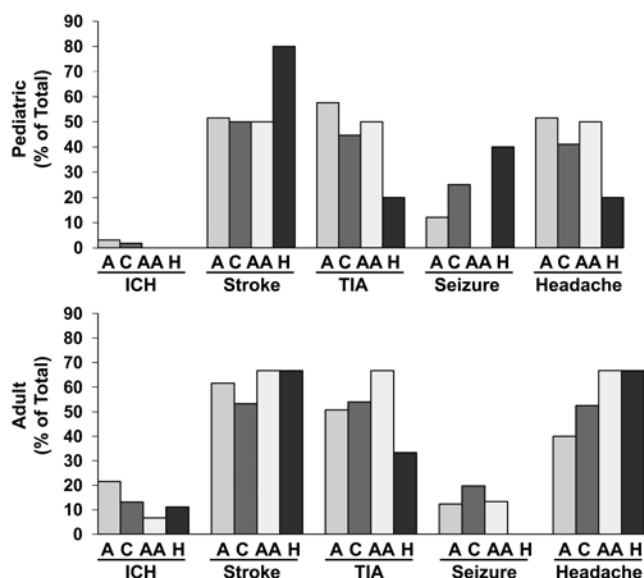


FIG. 2. Upper and Lower: Bar graphs showing presenting symptoms in 96 pediatric (upper) and 233 adult (lower) patients consisting of stroke, TIAs, intracerebral hemorrhage (ICH), seizures, and headaches. Adults presented significantly more often with intracerebral hemorrhage than pediatric patients ( $p < 0.05$ ). A = Asian; AA = African-American; C = Caucasian; H = Hispanic.

angiographic follow-up of 1.5 years (range 0.5–9.4 years, median 0.6 years), 99% of the bypasses were patent. The few occluded direct STA grafts were noted to have formed indirect collaterals supplying the territory at risk.

*Surgical Morbidity and Clinical Follow-Up*

Details of the surgical morbidity and mortality are

TABLE 1: Summary of cases involving morbidity and death\*

Case No.	Yr of Op	Patient Age (yrs)	Presenting Symptom	Disease Side	Op/Side	Complication	Location	Outcome
1	1992	43	stroke	bilat	direct/rt	hemorrhage	rt temporal	full recovery
2	1996	48	stroke/HA	bilat	direct vein graft/rt	hemorrhage	rt frontotemporal	died
3	2002	49	SAH	bilat	direct/rt	hemorrhage	rt frontal	died
4	2004	36	SAH	unilat	direct/lt	hemorrhage	lt parietal	full recovery
5	2004	37	stroke	bilat	direct/rt	hemorrhage	rt frontal	full recovery
6	2005	43	stroke	bilat	direct/lt	stroke	bifrontal	full recovery
7	2005	54	stroke	bilat	direct/lt	stroke	lt MCA	full recovery
8	2005	9	stroke	bilat	direct/lt	stroke	lt MCA/cerebellar	died
9	2006	39	stroke	bilat	direct/lt	stroke	bifrontal	full recovery
10	2006	55	stroke/HA	bilat	direct/rt	hemorrhage	rt temporal	full recovery
10	2006	55	stroke/HA	bilat	direct/lt	hemorrhage	lt temporal	rt hemiparesis, aphasia
11	2006	6	TIA/HA	bilat	direct/lt	hemorrhage	lt basal ganglia	full recovery
12	2006	46	TIA/HA	bilat	direct/lt	stroke	lt temporal	full recovery
13	2007	34	stroke	bilat	direct/rt	stroke	bilat MCA	severely disabled†
14	2007	52	stroke	unilat	direct/rt	stroke	rt PCA	hemianopsia
15	2007	5	stroke	bilat	indirect/rt	stroke	rt temporal	rt hemiparesis, aphasia

\* HA = headache.

† The patient in this case was discharged from the hospital and died of new strokes 6 months after surgery.

given in Table 1. A significant neurological deficit occurred in 15 patients undergoing 16 procedures (3.5% of procedures or 5.6% of patients).

Eight patients (3.0% [1.7% of procedures]) suffered a postoperative ischemic stroke. The stroke occurred in the surgical hemisphere in 4 patients and on the contralateral side in 4. Of the 8 patients suffering a new stroke, 4 had made a complete recovery when evaluated at 6 months.

Seven patients undergoing 8 procedures (2.6% [1.8% of procedures]) suffered a postoperative hemorrhage. All new hemorrhages occurred in previously ischemic territories, and all occurred in the surgical hemisphere. The hemorrhage developed during the surgery in 1 patient and between 4 hours and 10 days after surgery in 6 patients. Four of the 7 patients with a new hemorrhage had made a full recovery when examined 6 months after treatment. Two patients (0.75% [0.4% of procedures]) died of hemorrhage within 30 days of surgery .

Of interest, we observed transient neurological episodes (mainly dominant hemisphere) that started between Days 3 and 7 after surgery and lasted for up to 14 days without evidence of new infarct (nothing untoward documented on diffusion-weighted and later FLAIR images) or edema (nothing untoward documented on T2-weighted MR and FLAIR images). These episodes were shown in 9 patients (3.3% [2% of procedures]) and all patients made a full recovery.

*Moyamoya Syndrome*

Twenty-three patients had secondary moyamoya phenomenon associated with a syndrome (Table 2). Bilateral disease was found in 20 (85.7%) of the 23 patients, whereas 3 patients with neurofibromatosis (37.5% of those with neurofibromatosis) had unilateral disease (significantly



## Outcome after bypass surgery for moyamoya disease

**TABLE 2: Summary of secondary phenomena in patients with MMD stratified by age group**

Syndrome Categories	Age at Initial Presentation					
	All Pediatric Cases (0–18 yrs)		All Adult Cases (>18 yrs)		Overall Cohort	
	No.	(%)	No.	(%)	No.	(%)
neurofibromatosis	5	31.3	3	42.9	8	34.8
Down syndrome	3	18.8	3	42.9	6	26.1
primordial dwarfism	3	18.8	1	14.3	4	17.4
glycogen storage disorder Type Ia	1	6.3	0	0.0	1	4.3
Alagille syndrome	1	6.3	0	0.0	1	4.3
Russell-Silver syndrome	1	6.3	0	0.0	1	4.3
Hurler syndrome	1	6.3	0	0.0	1	4.3
MELAS	1	6.3	0	0.0	1	4.3
total	16	100.0	7	100.0	23	100.0

more unilaterally compared with other syndromes or entire cohort,  $p < 0.05$ ). The initial presenting symptoms were hemorrhage in 1 (4.8%), ischemic stroke in 18 (78.2%), TIA in 11 (52.4%), seizure in 9 (42.9%), and headaches in 10 (43.4%). The incidence of stroke among the mostly pediatric patients with an associated syndrome was higher than in the rest of the pediatric cohort (78.2 vs 51%,  $p = 0.06$ ).

One patient with mitochondrial MELAS<sup>31</sup> and 1 patient with Down syndrome (Cases 8 and 13 in Table 1) suffered postoperative strokes. The first patient died within 30 days of surgery and the second patient died 6 months after surgery due to late-onset complications. The surgical morbidity rate in this subgroup of patients was 8.7%.

### Univariate and Multivariate Analysis for Surgical Risk

Univariate and multivariate logistic regression analyses identified several baseline factors that demonstrated a trend toward increased risk of adverse surgical outcome, but these factors did not reach statistical significance. In the univariate analysis, patients presenting with TIA (OR 4.06,  $p = 0.19$ ) and stroke (OR 3.99,  $p = 0.19$ ) exhibited a trend toward greater risk of postoperative ischemic stroke; those presenting with ischemic stroke also exhibited a trend toward postoperative transient neurological episodes (OR 4.6,  $p = 0.15$ ); and those presenting with intracerebral hemorrhage exhibited a trend toward greater risk of postoperative hemorrhage (OR 2.7,  $p = 0.24$ ).

Interestingly, patients with a syndromic moyamoya phenomenon appeared to have higher risk of postoperative stroke (OR 4.16,  $p = 0.09$ ) and death (OR 6.29,  $p = 0.04$ ).

The aforementioned effect sizes were unchanged by multivariate analysis adjusting for sex, ethnicity, uni- versus bilateral disease, initial presentation, age, and type of surgery.

In the adult subset, ethnicity was not an independent risk factor for adverse surgical outcome. However, analysis of the pediatric subset demonstrated a trend among Caucasian pediatric patients for higher risk of any adverse postoperative event (OR 3.6,  $p = 0.26$ ), with a similar effect size in the multivariate model (OR 4.1,  $p = 0.24$ ).

Children presenting with stroke had a trend toward higher risk of any postoperative complication in both uni- and multivariate models (OR 2.7,  $p = 0.4$ ). Pediatric

patients undergoing indirect revascularization surgery had a trend toward being 2.5-fold more likely to suffer postoperative stroke than those undergoing direct revascularization ( $p = 0.5$ ).

### Long-Term Clinical Outcome

Overall, patients experienced a significant clinical improvement: mean preoperative mRS score of 1.62 and a mean mRS score of 0.83 at a mean follow-up of 4.9 years ( $p < 0.0001$ ) (Fig. 3A and B). Frequency analysis demonstrated that in 71.2% of the patients quality of life was improved, in 23.6% it remained unchanged, and in 5.2% it worsened (Fig. 3C). Patients presenting with a preoperative mRS score of 2 had a postoperative improvement in 76.2% of cases. Improvement by 1–2 points was observed in 67.8% of patients. In the multivariate analysis the strongest predictor of a good outcome (mRS Scores 0–2) after surgery was an mRS score  $\leq 2$  prior to surgery (OR 26.2,  $p < 0.0001$ ).

A significant reduction in TIAs was observed after treatment. Of the 171 patients presenting with TIAs, 82.5% were TIA free at 1 month and 91.8% at 1 year or later. Of the 43 pediatric patients presenting with TIAs, 93% were TIA free at 1 year or later.

A similar effect was observed in patients presenting with headaches. Of the 48% of patients presenting with headaches, > 80% were headache free at the last follow-up.

Late ischemic events were recorded in 2 patients (0.77%), leading to death in 1 patient 2 years after surgery. In the other patient a full recovery was made after a minor stroke. Late-onset hemorrhages occurred in 2 patients (0.77%), and a full recovery was documented in both. One patient died during a plastic surgery procedure for free flap skin transposition 6 months after an omental-cerebral transposition graft that was complicated by extensive scalp necrosis.

In summary, the overall incidence of ischemic stroke in the postoperative period (within 30 days of surgery) and up to the last follow-up was 3.8% (8 early and 2 late events) and for hemorrhagic events 3.4% (7 early and 2 late events). The overall mortality rate after surgical revascularization was 2.3% (3 early and 3 late deaths) during a mean follow-up period of 4.9 years. The cumulative 5-year Kaplan-

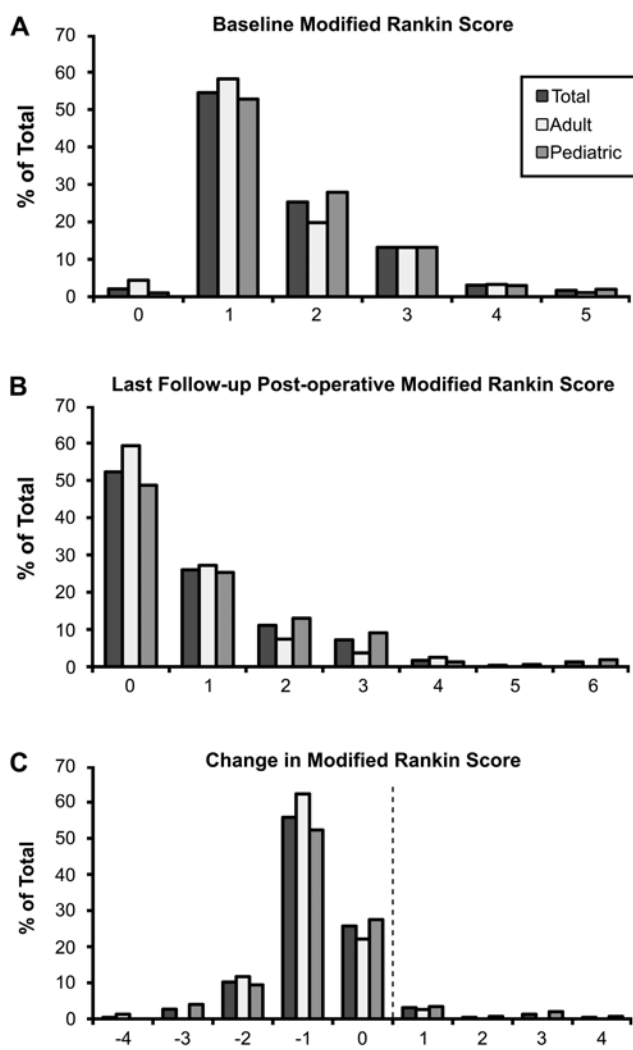


FIG. 3. Bar graphs demonstrating presurgical (A) and postsurgical (B) mRS scores obtained in 264 patients with a minimum of 6 months of follow-up. C: Overall 67% of the patients improved by 1–2 points on the mRS scale (change in mRS score of –1 or –2), whereas 23% remained unchanged (no change in mRS = 0). Status in only a few patients worsened after surgery (change in mRS score of 1–4). Values to the left of the dashed line represent no change or improvement in the mRS score.

Meier risk of perioperative or subsequent stroke or death was 5.5% (Fig. 4).

## Discussion

In this study, we have described a consecutive series of patients treated for MMD and moyamoya syndrome. Analysis of demographics and clinical characteristics at presentation was done in 329 patients undergoing 557 revascularization procedures. Outcome analysis, based on a minimum of 6 months of follow-up, is detailed in 264 patients undergoing 450 revascularization procedures.

### Patient Demographics and Presenting Symptoms

The ethnic distribution in our series was 59% Caucasian, 32% Asian, 5% African-American, and 4% Hispanic. Our demographic distribution differed from previously

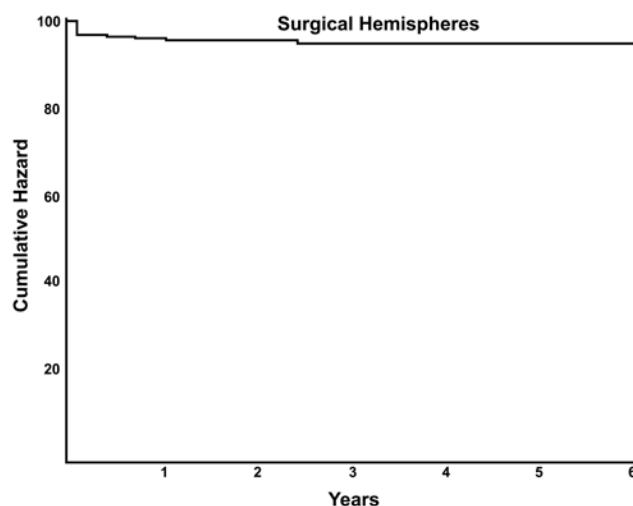


FIG. 4. Kaplan-Meier survival curve for any stroke or hemorrhage. The overall 5-year risk of any stroke or hemorrhage was 5.5%.

published “North American” series in which the majority of patients were Caucasian and African-American,<sup>5,11,47</sup> but was comparable to the epidemiological data published for California and Washington State, where the Asian population was more prominent.<sup>43</sup>

The mean age at presentation was 30.9 years with a bimodal age distribution that peaked between 10–19 years and between 30–39 years (Fig. 1A). The adult peak age distribution (range 30–39 years) was lower than that reported in a recent study on MMD in California and Washington State (range 55–59 years) based on administrative discharge databases.<sup>43</sup> This difference could possibly be explained by the fact that all of the patients in the current operative series were surgical candidates (typically younger), whereas in the epidemiological survey of Uchino et al.,<sup>44</sup> only 55% underwent revascularization. The female/male ratio of 2.5:1 in our series was comparable to other North American series,<sup>5,11</sup> but it was higher than that reported in the Asian literature (ratio range 1.2–1.8:1).<sup>2,28,45</sup> An interesting observation was that in our age group of 0–9 years, there was an almost equal distribution between females and males, which was found later in life to be 2.5:1.

Clinical manifestations were similar to those reported earlier in the literature including ischemic and hemorrhagic stroke, headache, and seizure. Ischemic events were the most common presenting symptom in adult (57%) and pediatric (51%) patients in our series, a finding described in other large series as well.<sup>2,11,37</sup> The incidence of hemorrhagic presentation in pediatric patients is known to be rare. In our 96 pediatric patients we found an incidence of 2.1% presenting with intracerebral hemorrhages, which was similar to previous large pediatric series with 2.8% intracranial hemorrhage.<sup>37</sup> Headache has been described as a symptom in up to 49% of patients,<sup>15</sup> and it can be associated with a hemorrhagic presentation of MMD<sup>15</sup> or as an independent presenting symptom<sup>35,38</sup> in children<sup>38</sup> and adult patients.<sup>15,18</sup> A significant number of our patients presented with a long history of mild to severe headaches (50% in adult and 44% in pediatric patients). When it is not associated with a hemorrhage, studies have suggested a relation

## Outcome after bypass surgery for moyamoya disease

to hypoperfusion and TIAs.<sup>33</sup> The ischemic penumbra can cause spreading cortical depression, which has been associated with migraine<sup>33</sup> and has also been described in MMD.<sup>35</sup> A different theory by Seol et al.<sup>39</sup> speculates that the dilation of meningeal and leptomeningeal collateral vessels stimulates dural nociceptors.

Twenty-three patients presented with “secondary moyamoya” or moyamoya phenomenon associated with a syndrome. A higher incidence of moyamoya phenomenon in patients with syndromes such as Down,<sup>19,41</sup> neurofibromatosis Type 1,<sup>37</sup> sickle cell disease,<sup>12</sup> and MELAS<sup>31</sup> has been described in the literature. Interestingly we found a higher incidence of unilateral manifestation in patients with neurofibromatosis Type 1 than in the rest of the cohort. Additionally the incidence of stroke in the mostly pediatric patients with an associated syndrome was higher than in the rest of the pediatric cohort (78.2 vs 51%,  $p = 0.06$ ).

### Surgical Results

The authors of previous studies have reported on successful revascularization results in patients with MMD.<sup>23,37</sup> In these high-risk patients, perioperative ischemia seems to be more common than in other cerebrovascular occlusive disease.<sup>36</sup> Much debate has centered on the safety and efficacy of various revascularization procedures. In adults, direct revascularization and, in children, indirect revascularization are considered the preferred surgical treatments.<sup>8,14</sup> A review of the pediatric literature failed to demonstrate a superiority or a lower surgical morbidity rate for either method.<sup>44</sup> Direct revascularization procedures are thought to provide immediate increase of blood flow to the ischemic brain. Direct revascularization is considered more complex, especially in pediatric patients with small donor and recipient vessels. Our philosophy has been to attempt direct revascularization in all patients. Only in pediatric patients < 4 years of age was it always necessary to perform indirect revascularization. Despite the fact that we performed direct bypass surgery in the vast majority (89.4%) of cases, the morbidity rate was low (3.5%), with a permanent deficit present in only 1.5% at 6-month follow-up. Our results compare favorably with older studies (perioperative complication rates > 7%<sup>17,24</sup>) and are comparable to most large studies,<sup>6,36,37</sup> with perioperative complications between 3.5 and 4% per surgical hemisphere.

Prior studies have attempted to determine risk factors that would predict surgical morbidity. Although not statistically significant in the uni- and multivariate analyses, preoperative TIA, stroke, and hemorrhage were associated with a higher risk for postoperative complications. In a large study of 368 revascularization procedures, Sakamoto et al.<sup>37</sup> found that a high frequency of preoperative TIA (> 1–4/month) (OR 4.8,  $p = 0.01$ ) and indirect revascularization (OR 5.8,  $p = 0.01$ ) were predictors of perioperative stroke risk. Frequent TIAs are a sign of cerebral hemodynamic instability and put the patient at higher risk of perioperative stroke if additional events such as hypercapnia or hypotension occur during the surgical procedure.<sup>17</sup> An additional strong predictor of adverse surgical events was the presence of a syndrome associated with moyamoya (stroke [OR 4.16  $p = 0.09$ ] and death [OR 6.29,  $p = 0.04$ ]). This had

been described previously for Down syndrome with MMD with a perioperative stroke rate of 12.5%.<sup>19</sup>

### Prevention of Future Events and Long-Term Outcome

The main goal of revascularization surgery in patients with MMD remains the prevention of future ischemic and hemorrhagic strokes and, potentially, limitation of disease progression. Previous studies have described an inevitable disease progression (without surgery) in 23.8%<sup>30</sup> and 38.9%<sup>22</sup> of patients. Equivocal or mild contralateral disease was the strongest predictor of disease progression.<sup>22</sup> The mean time to disease progression was 12.7 months in our study<sup>22</sup> and 60 months in that reported by Kuroda and colleagues.<sup>30</sup> The 5-year cumulative stroke risk in patients with medically treated hemispheres starting at 40% and up to 82% in patients with bilateral disease and stroke presentation.<sup>5,11,27</sup>

In the present study, contrary to these devastating numbers, the cumulative 5-year Kaplan-Meier risk of perioperative or subsequent stroke or death was 5.5%. Hallemeyer et al.<sup>11</sup> found a reduction of the cumulative 5-year stroke risk from 65% in medically treated hemispheres to 17% in surgically treated hemispheres ( $p = 0.02$ ). Kraemer et al.<sup>28</sup> reported a Kaplan-Meier risk of perioperative or subsequent stroke of 27.27% in the 1st month, which was stable thereafter. Comparison between our surgical study and the results for medically treated patients in the St. Louis study<sup>11</sup> or the European study<sup>27</sup> might not be fully valid due to differences in patient population, referral bias, and inclusion criteria and has to be interpreted with caution. Based on very limited data, patients with asymptomatic MMD have an estimated annual stroke risk of 3.2%.<sup>29</sup> Comparing this to the aforementioned cumulative risk data, we find that that surgery appears to be superior to observation already after 2 years (Fig. 4). These numbers, however, are generated from relatively small studies and have to be interpreted with caution.

The greatest controversy concerning surgery for MMD exists over the question of future hemorrhage prevention.<sup>7,16,21,34,48</sup> Rebleeding rates of 18%<sup>16</sup> and 14.3%<sup>14</sup> have been reported at mean follow-up periods of 4 and 6 years, respectively, after revascularization surgery. Even though these rates compare favorably with a risk of recurrent hemorrhage estimated to be 7%/person/year and a mortality rate of 28.6%<sup>26</sup> if left untreated, this result would not be satisfying. In our series, 2 patients suffered a late recurrent hemorrhage. Early reduction of the fragile moyamoya vessels is thought to be responsible for the reduction in rebleeding, and direct bypass surgery is suggested to be the preferred revascularization technique.<sup>14,21</sup> We have observed reduction of moyamoya vessels on the 4–6-month follow-up cerebral angiograms, sometimes with almost complete resolution of the moyamoya collaterals.<sup>46</sup> Based on our limited results, we can, however, not draw conclusions, and longer follow-up review will be needed.

Overall, 71.2% of patients had a significant improvement in quality of life, the strongest predictor being the preoperative mRS score (OR 26,  $p < 0.0001$ ). The patients also reported increased energy level and an increased ability to concentrate. It has been described that when left un-



treated, a deterioration of cognitive function is observed in children with MMD.<sup>32</sup> Provided that the preoperative Wechsler test IQ was > 70, the patients' statuses remained stable or improved during a mean follow-up period of 9.5 years after revascularization.<sup>32</sup>

### Conclusions

Evidence in the literature suggests that MMD is a progressive disease with a devastating natural history. In our cohort of 329 patients, the cumulative 5-year risk of any stroke or hemorrhage after revascularization surgery was 5.6%. This compares favorably to the natural history with a 5-year risk of repeated stroke or hemorrhage of up to 65% in symptomatic patients and 3.2%/year stroke risk in asymptomatic patients. Despite the lack of a prospective randomized trial to determine the efficacy of bypass surgery in patients with MMD, the available data support surgical treatment.

### Disclosure

This work was supported in part by Russell and Elizabeth Siegelman, Bernard and Ronni Lacroute, the William Randolph Hearst Foundation, and the Edward G. Hills fund.

### Acknowledgments

The authors thank Elizabeth Hoyte for preparation of the figures and Dr. Bruce Schaar for critical reading of the manuscript.

### References

- Anonymous: United Kingdom transient ischaemic attack (UK-TIA) aspirin trial: interim results. UK-TIA Study Group. **Br Med J (Clin Res Ed)** **296**:316–320, 1988
- Baba T, Houkin K, Kuroda S: Novel epidemiological features of moyamoya disease. **J Neurol Neurosurg Psychiatry** **79**:900–904, 2008
- Chang SD, Steinberg GK: Superficial temporal artery to middle cerebral artery anastomosis. **Techniques in Neurosurgery** **6**: 86–100, 2000
- Chang SD, Steinberg GK: Surgical management of moyamoya disease. **Contemporary Neurosurgery** **22**:1–9, 2000
- Chiu D, Shedden P, Bratina P, Grotta JC: Clinical features of moyamoya disease in the United States. **Stroke** **29**:1347–1351, 1998
- Choi JU, Kim DS, Kim EY, Lee KC: Natural history of moyamoya disease: comparison of activity of daily living in surgery and non surgery groups. **Clin Neurol Neurosurg** **99 (2 Suppl)**:S11–S18, 1997
- Fujii K, Ikezaki K, Irikura K, Miyasaka Y, Fukui M: The efficacy of bypass surgery for the patients with hemorrhagic moyamoya disease. **Clin Neurol Neurosurg** **99 (2 Suppl)**:S194–S195, 1997
- Fukui M: Current state of study on moyamoya disease in Japan. **Surg Neurol** **47**:138–143, 1997
- Fukui M: Guidelines for the diagnosis and treatment of spontaneous occlusion of the circle of Willis ('moyamoya' disease). Research Committee on Spontaneous Occlusion of the Circle of Willis (Moyamoya Disease) of the Ministry of Health and Welfare, Japan. **Clin Neurol Neurosurg** **(2 Suppl)** **99**:S238–S240, 1997
- Golby AJ, Marks MP, Thompson RC, Steinberg GK: Direct and combined revascularization in pediatric moyamoya disease. **Neurosurgery** **45**:50–60, 1999
- Hallemeier CL, Rich KM, Grubb RL Jr, Chicoine MR, Moran CJ, Cross DT III, et al: Clinical features and outcome in North American adults with moyamoya phenomenon. **Stroke** **37**:1490–1496, 2006
- Hankinson TC, Bohman L-E, Heyer G, Licursi M, Ghatan S, Feldstein NA, et al: Surgical treatment of moyamoya syndrome in patients with sickle cell anemia: outcome following encephaloduroarteriosynangiosis. **J Neurosurg Pediatr** **1**: 211–216, 2008
- Hoffman HJ: Moyamoya disease and syndrome. **Clin Neurol Neurosurg** **99 (2 Suppl)**:S39–S44, 1997
- Houkin K, Kamiyama H, Abe H, Takahashi A, Kuroda S: Surgical therapy for adult moyamoya disease. Can surgical revascularization prevent the recurrence of intracerebral hemorrhage? **Stroke** **27**:1342–1346, 1996
- Hung CC, Tu YK, Su CF, Lin LS, Shih CJ: Epidemiological study of Moyamoya disease in Taiwan. **Clin Neurol Neurosurg** **99**:S23–S25, 1997
- Ikezaki K, Fukui M, Inamura T, Kinukawa N, Wakai K, Ono Y: The current status of the treatment for hemorrhagic type moyamoya disease based on a 1995 nationwide survey in Japan. **Clin Neurol Neurosurg** **99 (2 Suppl)**:S183–S186, 1997
- Iwama T, Hashimoto N, Yonekawa Y: The relevance of hemodynamic factors to perioperative ischemic complications in childhood moyamoya disease. **Neurosurgery** **38**:1120–1126, 1996
- Iwama T, Yoshimura S: Present status of Moyamoya disease in Japan. **Acta Neurochir Suppl** **103**:115–118, 2008
- Jea A, Smith ER, Robertson R, Scott RM: Moyamoya syndrome associated with Down syndrome: outcome after surgical revascularization. **Pediatrics** **116**:e694–e701, 2005
- Karasawa J, Touho H, Ohnishi H, Miyamoto S, Kikuchi H: Long-term follow-up study after extracranial-intracranial bypass surgery for anterior circulation ischemia in childhood moyamoya disease. **J Neurosurg** **77**:84–89, 1992
- Kawaguchi S, Okuno S, Sakaki T: Effect of direct arterial bypass on the prevention of future stroke in patients with the hemorrhagic variety of moyamoya disease. **J Neurosurg** **93**: 397–401, 2000
- Kelly ME, Bell-Stephens TE, Marks MP, Do HM, Steinberg GK: Progression of unilateral moyamoya disease: a clinical series. **Cerebrovasc Dis** **22**:109–115, 2006
- Khan N, Schuknecht B, Boltshauser E, Capone A, Buck A, Imhof HG, et al: Moyamoya disease and Moyamoya syndrome: experience in Europe; choice of revascularisation procedures. **Acta Neurochir (Wien)** **145**:1061–1071, 2003
- Kim SH, Choi J, Yang K, Kim T, Kim D: Risk factors for post-operative ischemic complications in patients with moyamoya disease. **J Neurosurg** **103**:433–438, 2005
- Kim SK, Wang KC, Kim DG, Paek SH, Chung HT, Han MH, et al: Clinical feature and outcome of pediatric cerebrovascular disease: a neurosurgical series. **Childs Nerv Syst** **16**:421–428, 2000
- Kobayashi E, Saeki N, Oishi H, Hirai S, Yamaura A: Long-term natural history of hemorrhagic moyamoya disease in 42 patients. **J Neurosurg** **93**:976–980, 2000
- Kraemer M, Heienbrok W, Berlit P: Moyamoya disease in Europeans. **Stroke** **39**:3193–3200, 2008
- Kuriyama S, Kusaka Y, Fujimura M, Wakai K, Tamakoshi A, Hashimoto S, et al: Prevalence and clinicoepidemiological features of moyamoya disease in Japan: findings from a nationwide epidemiological survey. **Stroke** **39**:42–47, 2008
- Kuroda S, Hashimoto N, Yoshimoto T, Iwasaki Y: Radiological findings, clinical course, and outcome in asymptomatic moyamoya disease: results of multicenter survey in Japan. **Stroke** **38**:1430–1435, 2007
- Kuroda S, Ishikawa T, Houkin K, Nanba R, Hokari M, Iwasaki Y: Incidence and clinical features of disease progression in adult moyamoya disease. **Stroke** **36**:2148–2153, 2005



## Outcome after bypass surgery for moyamoya disease

31. Longo N, Schrijver I, Vogel H, Pique LM, Cowan TM, Pascual M, et al: Progressive cerebral vascular degeneration with mitochondrial encephalopathy. **Am J Med Genet A** **146**:361–367, 2008
32. Matsushima Y, Aoyagi M, Nariai T, Takada Y, Hirakawa K: Long-term intelligence outcome of post-encephalo-duro-arterio-synangiosis childhood moyamoya patients. **Clin Neurol Neurosurg (2 Suppl)** **99**:S147–S150, 1997
33. Olesen J, Friberg L, Olsen TS, Andersen AR, Lassen NA, Hansen PE, et al: Ischaemia-induced (symptomatic) migraine attacks may be more frequent than migraine-induced ischaemic insults. **Brain** **116**:187–202, 1993
34. Otawara Y, Ogasawara K, Seki K, Kibe M, Kubo Y, Ogawa A: Intracerebral hemorrhage after prophylactic revascularization in a patient with adult moyamoya disease. **Surg Neurol** **68**:335–337, 2007
35. Park-Matsumoto YC, Tazawa T, Shimizu J: Migraine with aura-like headache associated with moyamoya disease. **Acta Neurol Scand** **100**:119–121, 1999
36. Sakamoto T, Kawaguchi M, Kurehara K, Kitaguchi K, Furuya H, Karasawa J: Risk factors for neurologic deterioration after revascularization surgery in patients with moyamoya disease. **Anesth Analg** **85**:1060–1065, 1997
37. Scott RM, Smith JL, Robertson RL, Madsen JR, Soriano SG, Rockoff MA: Long-term outcome in children with moyamoya syndrome after cranial revascularization by pial synangiosis. **J Neurosurg** **100**:142–149, 2004
38. Seol HJ, Wang KC, Kim SK, Hwang YS, Kim KJ, Cho BK: Headache in pediatric moyamoya disease: review of 204 consecutive cases. **J Neurosurg** **103**:439–442, 2005
39. Steinberg GK, Ogilvy CS, Shuer LM, Connolly ES Jr, Solomon RA, Lam A, et al: Comparison of endovascular and surface cooling during unruptured cerebral aneurysm repair. **Neurosurgery** **55**:307–315, 2004
40. Suzuki J, Kodama N: Moyamoya disease—a review. **Stroke** **14**:104–109, 1983
41. Takanashi J, Sugita K, Honda A, Niimi H: Moyamoya syndrome in a patient with Down syndrome presenting with chorea. **Pediatr Neurol** **9**:396–398, 1993
42. Takeuchi K, Shimizu K: Hypogenesis of bilateral internal carotid arteries. **No To Shinkei** **9**:37–43, 1957
43. Uchino K, Johnston SC, Becker KJ, Tirschwell DL: Moyamoya disease in Washington State and California. **Neurology** **65**:956–958, 2005
44. Veeravagu A, Guzman R, Patil CG, Hou LC, Lee M, Steinberg GK: Moyamoya disease in pediatric patients: outcomes of neurosurgical interventions. **Neurosurg Focus** **24**:E16, 2008
45. Wakai K, Tamakoshi A, Ikezaki K, Fukui M, Kawamura T, Aoki R, et al: Epidemiological features of moyamoya disease in Japan: findings from a nationwide survey. **Clin Neurol Neurosurg** **99 (2 Suppl)**:S1–S5, 1997
46. Wang MY, Steinberg GK: Rapid and near-complete resolution of moyamoya vessels in a patient with moyamoya disease treated with superficial temporal artery-middle cerebral artery bypass. **Pediatr Neurosurg** **24**:145–150, 1996
47. Yilmaz EY, Pritz MB, Bruno A, Lopez-Yunez A, Biller J: Moyamoya: Indiana University Medical Center experience. **Arch Neurol** **58**:1274–1278, 2001
48. Yoshida Y, Yoshimoto T, Shirane R, Sakurai Y: Clinical course, surgical management, and long-term outcome of moyamoya patients with rebleeding after an episode of intracerebral hemorrhage: an extensive follow-up study. **Stroke** **30**:2272–2276, 1999

---

Manuscript submitted December 9, 2008.

Accepted April 14, 2009.

Please include this information when citing this paper: published online May 22, 2009; DOI: 10.3171/2009.4.JNS081649.

Address correspondence to: Gary K. Steinberg, M.D., Ph.D., Department of Neurosurgery, Stanford University School of Medicine, 300 Pasteur Drive, R281 Stanford, California 94305-5487. email: gsteinberg@stanford.edu.